

## Bifidobacterium bacteraemia is rare with routine probiotics use in preterm infants

Acuna-Gonzalez, Antia; Kujawska, Magdalena; Youssif, Mayada; Atkinson, Thomas; Grundy, Sara; Hutchison, Alexandra; Tremlett, Catherine; Clarke, Paul; Hall, Lindsay J.

DOI:

[10.1016/j.anaerobe.2023.102713](https://doi.org/10.1016/j.anaerobe.2023.102713)

License:

Creative Commons: Attribution (CC BY)

### Document Version

Publisher's PDF, also known as Version of record

### Citation for published version (Harvard):

Acuna-Gonzalez, A, Kujawska, M, Youssif, M, Atkinson, T, Grundy, S, Hutchison, A, Tremlett, C, Clarke, P & Hall, LJ 2023, 'Bifidobacterium bacteraemia is rare with routine probiotics use in preterm infants: A further case report with literature review', *Anaerobe*, vol. 80, 102713. <https://doi.org/10.1016/j.anaerobe.2023.102713>

[Link to publication on Research at Birmingham portal](#)

### General rights

Unless a licence is specified above, all rights (including copyright and moral rights) in this document are retained by the authors and/or the copyright holders. The express permission of the copyright holder must be obtained for any use of this material other than for purposes permitted by law.

- Users may freely distribute the URL that is used to identify this publication.
- Users may download and/or print one copy of the publication from the University of Birmingham research portal for the purpose of private study or non-commercial research.
- User may use extracts from the document in line with the concept of 'fair dealing' under the Copyright, Designs and Patents Act 1988 (?)
- Users may not further distribute the material nor use it for the purposes of commercial gain.


Where a licence is displayed above, please note the terms and conditions of the licence govern your use of this document.

When citing, please reference the published version.

### Take down policy

While the University of Birmingham exercises care and attention in making items available there are rare occasions when an item has been uploaded in error or has been deemed to be commercially or otherwise sensitive.

If you believe that this is the case for this document, please contact [UBIRA@lists.bham.ac.uk](mailto:UBIRA@lists.bham.ac.uk) providing details and we will remove access to the work immediately and investigate.



## Case Report

## *Bifidobacterium* bacteraemia is rare with routine probiotics use in preterm infants: A further case report with literature review

Antia Acuna-Gonzalez<sup>a</sup>, Magdalena Kujawska<sup>b</sup>, Mayada Youssif<sup>c</sup>, Thomas Atkinson<sup>a</sup>, Sara Grundy<sup>c</sup>, Alexandra Hutchison<sup>c</sup>, Catherine Tremlett<sup>c</sup>, Paul Clarke<sup>c, d, \*\*, \*</sup>, Lindsay J. Hall<sup>a, b, d, \*</sup>

<sup>a</sup> Gut Microbes & Health, Quadram Institute Bioscience, Norwich Research Park, Norwich, NR4 7UQ, UK

<sup>b</sup> Intestinal Microbiome, School of Life Sciences, ZIEL – Institute for Food & Health, Technical University of Munich, Freising, 80333, Germany

<sup>c</sup> Neonatal Intensive Care Unit, Norfolk and Norwich University Hospitals NHS Foundation Trust, Norwich, NR4 7UY, UK

<sup>d</sup> Norwich Medical School, University of East Anglia, Norwich Research Park, Norwich, NR4 7TJ, UK

## ARTICLE INFO

## Article history:

Received 10 November 2022

Received in revised form

31 January 2023

Accepted 2 February 2023

Available online 6 February 2023

Handling Editor: Leandro Araujo Lobo

## ABSTRACT

Prophylactic administration of oral probiotics is associated with significant reductions in the morbidity and mortality of necrotising enterocolitis in preterm infants. We document the first case of *Bifidobacterium longum* subsp. *infantis* sub-clinical bacteraemia, in an extremely low birth weight preterm infant, since introduction of routine probiotic treatment at the Norfolk and Norwich University Hospital 10 years ago. Whole genome comparisons confirmed the isolated strain likely originated from the probiotic product.

© 2023 The Authors. Published by Elsevier Ltd. This is an open access article under the CC BY license (<http://creativecommons.org/licenses/by/4.0/>).

## 1. Introduction

Neonates, and preterm infants in particular, often develop life-threatening conditions due to an immature gut microbiota and immune system [1]. Necrotising enterocolitis (NEC), the most frequent gastrointestinal emergency in preterm infants, is a multifactorial condition associated with overgrowth of potentially pathogenic microbiota members, and may result in intestinal perforation, and abdominal cavity infection [2]. In recent years, oral probiotics are estimated to be used in 17% of tertiary-level Neonate Intensive Care Units (NICUs) in England, according to a 2018 survey [3], to alter gut microbiota profiles beneficially, and to improve preterm health outcomes reducing NEC-associated morbidity and mortality by  $\geq 50\%$  [4,5]. *Bifidobacterium* species and strains are included in many currently available probiotic formulations owing to their long-standing safety track record, ability to breakdown specific dietary components (e.g. human milk oligosaccharides), and their anti-inflammatory and immunomodulatory properties

[6]. Although classed as 'generally recognised as safe', there are concerns of potential *Bifidobacterium* probiotic-associated bacteraemia and/or sepsis in at-risk infants, however there are only a few documented cases to date [7,8].

Here, we report a further case of non-fatal *Bifidobacterium* bacteraemia associated with probiotic treatment in an extremely low birth weight infant. *B. longum* subsp. *infantis* was isolated from a blood culture and, using comparative genomics, we confirmed that the isolate recovered from the infant originated from the probiotic formulation.

## 2. Description of the case

A female infant weighing 490 g was delivered at 24 weeks and 4 days' gestation by lower segment Caesarean section. She was small for gestational age (birth weight <10th percentile). She was admitted to NICU, required intubation and ventilation, and developed pneumothorax and pneumatocoles. The admission blood culture was negative. Umbilical venous and arterial catheters were sited on the first postnatal day of life (DOL 1) and intravenous parenteral nutrition feeds commenced. On DOL 11 the umbilical arterial catheter was removed and on DOL 15 the umbilical venous catheter was replaced by a peripherally-inserted central venous catheter (Fig. 1). Enteral feeding with maternal colostrum commenced on DOL 2 but were stopped the same day due to

\* Corresponding author. Gut Microbes & Health, Quadram Institute Bioscience, Norwich Research Park, Norwich, NR4 7UQ, UK.

\*\* Corresponding author. Neonatal Intensive Care Unit, Norfolk and Norwich University Hospitals NHS Foundation Trust, Norwich, NR4 7UY, UK.

E-mail addresses: [PAUL.CLARKE@nuh.nhs.uk](mailto:PAUL.CLARKE@nuh.nhs.uk) (P. Clarke), [Lindsay.Hall@quadram.ac.uk](mailto:Lindsay.Hall@quadram.ac.uk) (L.J. Hall).

periodic bilious aspirates, and maternal colostrum/breastmilk was only restarted on DOL 13 when the bilious aspirates cleared. The infant received a first dose of probiotics on DOL 2 and supplementation continued daily despite enteral feeds being withheld. Multi-species oral probiotics (*Lactobacillus* and *Bifidobacterium* spp.) have been routinely used in our NICU for prophylaxis of NEC since January 2013. Since 2016, we have used the commercial product Labinc Drops™ (Biofloratech, UK). The daily dosage of Labinc Drops given to the infant (5 drops; ~0.2 mL) provided ~2 billion colony forming units of live bacteria (*Lactobacillus acidophilus*  $0.67 \times 10^9$ , *Bifidobacterium bifidum*  $0.67 \times 10^9$ , and *Bifidobacterium longum* subsp. *infantis*  $0.67 \times 10^9$ ). On DOL 15 an unexpected increase in C-reactive protein (CRP), from 7 to 52 mg/L, was noted in the routine daily blood panel. This prompted an infection screen and empirical commencement of antibiotics (Fig. 1). Concomitant complete blood count revealed a high white blood cell count,  $35 \times 10^9/L$  (neutrophils  $25.8 \times 10^9/L$ ), and low platelets  $112 \times 10^9/L$ . Manual blood film examination showed neutrophil leucocytosis and neutrophils showed a left shift. She had no overt clinical signs or symptoms of infection at this time. Her peripheral blood culture isolated *Bifidobacterium* spp. after 2 days' incubation (BacT/ALERT® PF Plus (PF Plus), bioMérieux Inc., USA). She remained stable over the next 3 days and CRP fell to 32 then 22 mg/L. However, on DOL 18, she developed acute abdominal distension and increased ventilatory requirements. Abdominal perforation was suspected, enteral feeds, probiotics, and dexamethasone were stopped, and abdominal x-ray confirmed pneumoperitoneum. CRP rose again to 52 mg/L. A diagnosis of spontaneous ileal perforation was made at laparotomy on DOL 19, at which an ileostomy was formed. Surgical histopathology excluded NEC and was consistent with isolated spontaneous intestinal perforation (SIP). A repeat blood culture taken pre-operatively (DOL 18) grew *Staphylococcus epidermidis* after 1 day incubation but was negative for *Bifidobacterium* spp. Piperacillin-tazobactam (90 mg/kg 8 hourly) was substituted for Cefotaxime, and given for 5 days, and vancomycin continued for 11 days. CRP peaked at 95 mg/L on DOL 19. Probiotic treatment resumed on DOL 23, and enteral feeding on DOL 25 (Fig. 1). The infant was discharged home 7 months after birth weighing 4.2 Kg; at discharge she required no supplementary oxygen, was being fed via

nasogastric tube, and still had her stoma *in situ*.

The *Bifidobacterium* spp. isolate recovered from the infant's blood culture (DOL 15) was retrieved from the clinical diagnostic laboratory and cultured on de Man-Rogosa-Sharpe (MRS) (Oxoid) medium supplemented with 0.5 g/L cysteine-HCL for 48h under anaerobic conditions (A20 workstation, Don Whitley Scientific, UK), and subjected to whole genome sequencing (WGS) (Illumina Nextseq500) in our laboratory. Independently, the content of the Labinc Drops™ was inoculated on MRS agar and incubated anaerobically as above, with the resulting isolates subjected to WGS (Illumina HiSeq 2500) at the Wellcome Trust Sanger Institute (Hinxton, UK). Additionally, the publicly-available sequence for the Danisco Florafit *B. longum* subsp. *infantis* Bi-26 contained in the Labinc Drops™ (accession number: CP054425.1) was retrieved from NCBI Genome database [9]. The genomes of *Bifidobacterium* isolates recovered from both the infant's blood culture and the Labinc Drops™ were compared with that of *B. longum* subsp. *infantis* Bi-26 using the average nucleotide identity (ANI) algorithm [10] and single nucleotide polymorphism (SNP) variant calling [11]. This analysis revealed the ANI score above 99.9% and the SNP distance of less than 10 SNPs between the three genomes, leading to the firm conclusion that the isolate in infant's blood originated from the commercial probiotic product used in our NICU (Fig. 2).

For further corroboration, the genomes were screened for the presence of antimicrobial resistance genes against both an in-house sequence collection and the CARD database [12], which revealed the presence of putative homologues associated with conferring of resistance to tetracycline (*tet(M)/tet(W)/tet(O)/tet(S)*) [13] and rifampicin (*rpoB*) [14], (Fig. 3). These findings were in line with previous reports for bifidobacteria showing very limited antibiotic resistance profiles, including for those strains used in probiotics [15,16].

### 3. Discussion

This report describes a rare case of probiotic-associated bacteraemia in a routinely probiotic-supplemented extremely low birth weight preterm infant whose initial clinical manifestation comprised only abnormal laboratory markers. The bacteraemia was rapidly cleared with a standard antibiotic combination. WGS and

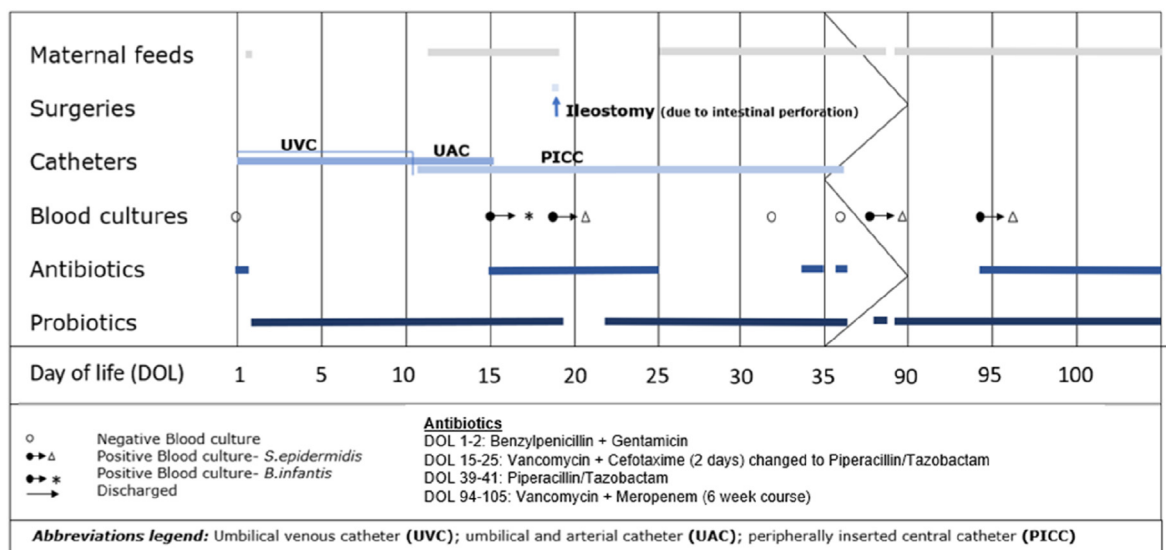


Fig. 1. Timeline of the infant's bacteraemia episodes, diagnostic, and treatment pathway. Umbilical venous catheter (UCV), umbilical arterial catheter (UAC), and peripherally-inserted central venous catheter (PICC). Surgery details; DOL 18 spontaneous intestinal perforation (SIP), and DOL 19 laparotomy (+ileostomy).

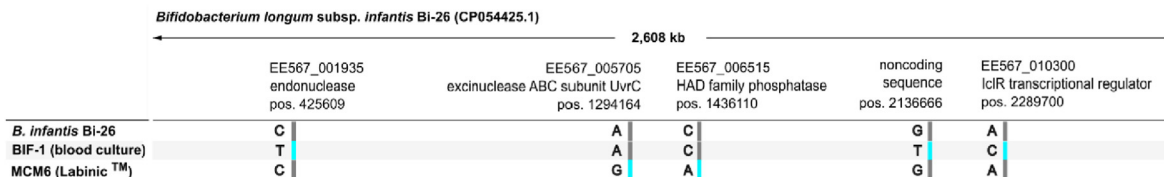


Fig. 2. Graphical representation of SNP distribution over *B. longum* subsp. *infantis* genomes.

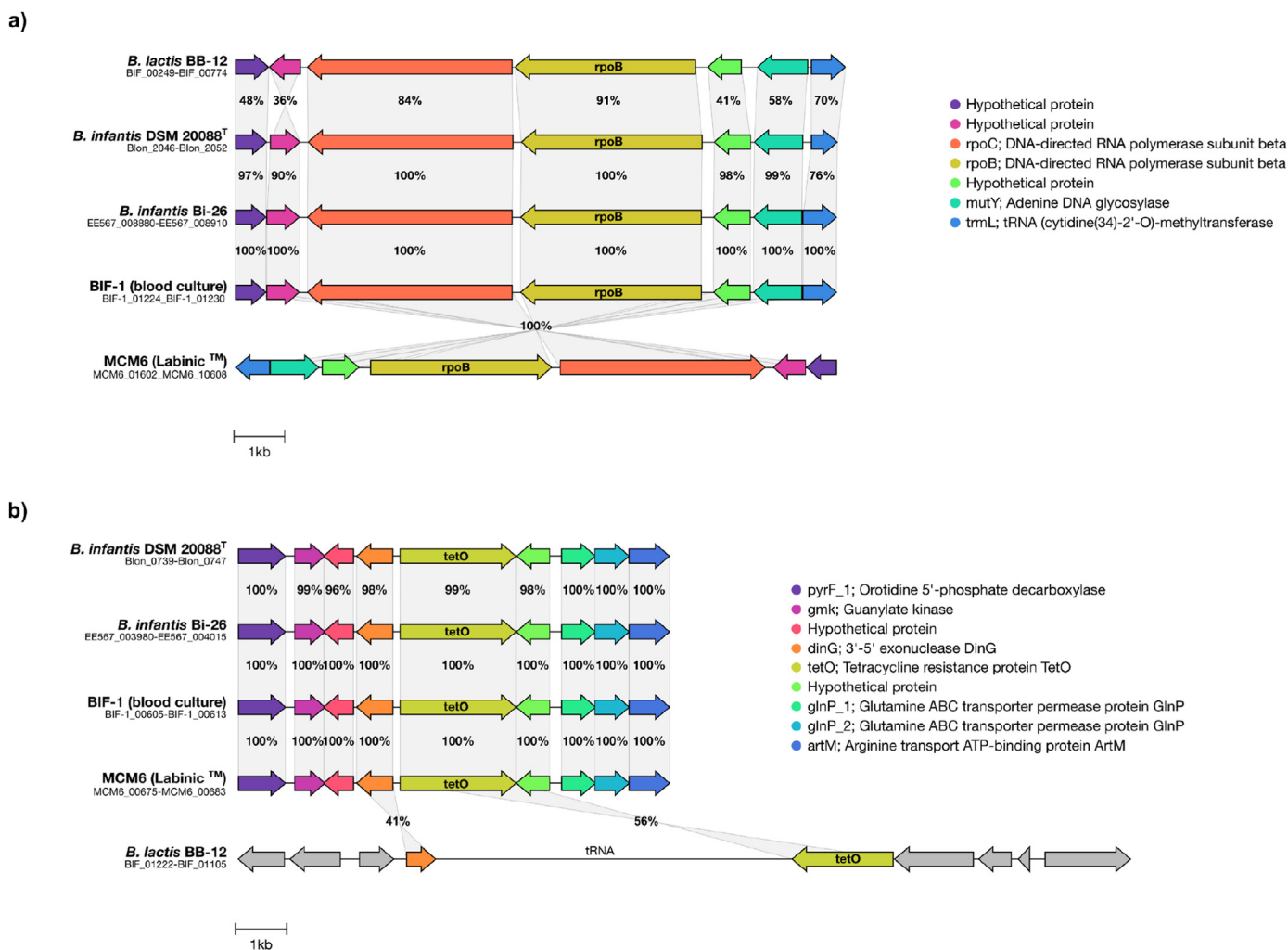


Fig. 3. Representation of the chromosomal regions flanking putative genes associated with conferring resistance to (a) rifampicin (*rpoB*) and (b) tetracycline (*tetO*) in selected *Bifidobacterium* strains, including isolates from this report and known probiotics (*B. infantis* Bi-26 and *B. lactis* BB-12). Genes with amino acid identity over 30% are represented with the same colour. (For interpretation of the references to colour in this figure legend, the reader is referred to the Web version of this article.)

analysis confirmed the blood isolate to be the identical strain present in the given commercial probiotic supplement (Labinic Drops™). In the last 10 years, to the best of our knowledge, only three previous case reports of *B. longum* subsp. *infantis* sepsis or bacteraemia have been published, comprising a total of six very low birth weight (<1500 g) preterm infants, all of whom also fully recovered (Table 1). In 5 of the 6 cases, infants had suffered from NEC or SIP, with necrosis, inflammation or surgical intervention suggested as the primary causes of bacterial translocation [17,18]. Histopathological difference between NEC and SIP can be unclear, which may lead to SIP and NEC misclassification [19,20].

While the infant presented in this case report also suffered temporally-proximate bowel perforation requiring surgery, we

have shown that the raised CRP and *Bifidobacterium*-positive blood culture predated the perforation by 3 days. The development of local oedema and inflammation in the infant's ileum could have allowed translocation of *Bifidobacterium* from the gut, as these exact features were observed histopathologically in the resected gut segment. We estimate that globally to date, hundreds of thousands of preterm infants have now received multiple doses of probiotics prophylactically during their NICU stays, and yet reports of probiotic bacterial sepsis/bacteraemia are extremely rare. This highlights the exceptionally strong safety record of probiotics as an effective NEC treatment, now including our own experience with only this single case of sub-clinical bacteraemia among >1000 infants treated with *Bifidobacterium*-*Lactobacillus* combination

**Table 1**Description of 6 different *B. longum* subsp. *infantis* related sepsis and bacteraemia cases in preterm infants within the last 10 years.

Reference	Etiologic agent	Infection type	Gestational age, sex, Weigh, birth method	Underlying conditions	Probiotic treatment (days)	Antibiotic Treatment (days)	Outcome
[21]	<i>B. longum</i> subsp. <i>infantis</i>	Sepsis, Bacteraemia,	(1) 24, Male, 730 g, vaginal	(1) sepsis, pneumoperitoneum, features of NEC	(1,) 8	(1, 2, 3) Not specified	(1) Recovered
		Sepsis	(2) 23, Male, 500 g, vaginal	(2) apnea, bradycardia, and temperature	(2) 12		(2) Recovered
			(3) 24, Female, 697 g, C,-section	(3) NEC, Bowel perforations, ventilation	(3) 46		(3) Recovered
[22]	<i>B. longum</i> subsp. <i>infantis</i>	Sepsis,	(1) 26, Female, 867 g, vaginal	(1) tachycardia, ileus, intestinal distention, anastomosis, intestinal necrosis	(1) 14	(1) 7, Ceftazidime & Vancomycin; 7, Imipenem	(1) Recovered
		Bacteraemia	(2) 28, female, 1090 g, C-section,	(2) nasal O <sub>2</sub> , abdominal distention, intubation, transfusion, leukopenia, pneumatis intestinalis, NEC, necrosis, jejunal perforation, reinsertion of small intestine, anastomosis	(2) 10	(2) 3, Amoxicillin, Gentamicin; N/A, Ceftazidime, Amikacin, and Metronidazole	(2) Recovered
[23]	<i>B. longum</i> subsp. <i>infantis</i>	Bacteraemia	28, Female, 1090 g, C-section	Abdomen distension, coagulopathy (NEC)	4	(not specified), Ceftazidime, Amikacin, Metronidazole	Recovered

probiotics in our centre over the past decade, and despite individual infants typically receiving daily doses of probiotics for a duration of at least 30–60 days depending upon birth gestation. Many studies have shown that *Bifidobacterium* is a beneficial member of the early life gut microbiota, and its presence is associated with numerous health benefits including strengthening of the neonatal gut barrier and induction of homeostatic and anti-inflammatory immune responses [24–27]. This contrasts with the typical pro-inflammatory cascade associated with non-probiotic species bacterial sepsis. Moreover, regulations for probiotics state that the strains used must not have acquired antibiotic resistance. The *B. longum* subsp. *infantis* contained within the Labinic formulation fulfils this requirement, which links to its rapid elimination from subsequent blood cultures after second-line antibiotics.

We have documented a rare case of non-fatal probiotic-associated bacteraemia caused by a *B. longum* subsp. *infantis* in an extremely low birth weight preterm infant. It was isolated from blood cultures taken due to a raised CRP but no clinical signs, and genomic approaches confirmed the probiotic provenance of the bifidobacterial strain detected in the infant's blood. The portal of its entry into the bloodstream was most likely translocation at the site of evolving gut pathology.

### Source of funding

L.J.H. is supported by Wellcome Trust Investigator Awards 100974/C/13/Z and 220876/Z/20/Z; the Biotechnology and Biological Sciences Research Council (BBSRC), Institute Strategic Programme Gut Microbes and Health BB/R012490/1, and its constituent projects BBS/E/F/000PR10353 and BBS/E/F/000PR10356.

### CRedit authorship contribution statement

**Antia Acuna-Gonzalez:** Investigation, Formal analysis, Methodology, Writing – original draft, Writing – review & editing. **Magdalena Kujawska:** Investigation, Formal analysis, Data curation, Writing – original draft, Writing – review & editing. **Mayada Youssif:** Investigation, Formal analysis, Writing – review & editing. **Thomas Atkinson:** Investigation, Writing – review & editing. **Sara**

**Grundy:** Investigation, Methodology, Resources, Writing – review & editing. **Alexandra Hutchison:** Methodology, Writing – review & editing. **Catherine Tremlett:** Investigation, Methodology, Resources, Writing – review & editing. **Paul Clarke:** Investigation, Formal analysis, Resources, Supervision, Conceptualization, Project administration, Writing – original draft, Writing – review & editing. **Lindsay J. Hall:** Formal analysis, Resources, Supervision, Funding acquisition, Conceptualization, Investigation, Project administration, Writing – original draft, Writing – review & editing.

### Declaration of competing interest

The authors declare no conflict of interest relevant to this article.

### Data availability

Genomic sequence data is available via project number; PRJNA882778

### References

- [1] S.X. Cho, et al., The immunological landscape in necrotising enterocolitis, *Expet Rev. Mol. Med.* 18 (2016) 1–17.
- [2] S.C. Papillon, Scott S. Short, H. Ford, *Necrotizing Enterocolitis*. Newborn Surgery, fourth ed., 2017, pp. 653–659, 2017.
- [3] S.D. Duffield, P. Clarke, Current use of probiotics to prevent necrotising enterocolitis, *Arch. Dis. Child. Fetal Neonatal Ed.* 104 (2) (2019) F228.
- [4] C. Robertson, et al., Incidence of necrotising enterocolitis before and after introducing routine prophylactic *Lactobacillus* and *Bifidobacterium* probiotics. *Archives of disease in childhood, Fetal Neonatal Ed.* 105 (4) (2020) 380–386 (1468-2052 (Electronic)).
- [5] M.A. Underwood, Probiotics and the prevention of necrotizing enterocolitis, *J. Pediatr. Surg.* 54 (3) (2019) 405–412.
- [6] M.A.K. Azad, et al., Probiotic Species in the Modulation of Gut Microbiota: an Overview, vol. 2018, *BioMed research international*, 2018, p. 9478630, 9478630.
- [7] M. D'agostin, et al., Invasive infections associated with the use of probiotics in children: a systematic review, *Children* 8 (10) (2021) 1–13.
- [8] T. Kulkarni, et al., Probiotic sepsis in preterm neonates—a systematic review, *Eur. J. Pediatr.* 181 (6) (2022) 2249–2262.
- [9] E.W. Sayers, et al., Database resources of the national center for Biotechnology information, *Nucleic Acids Res.* 48 (D1) (2020) D9–D16.
- [10] C. Jain, et al., High throughput ANI analysis of 90K prokaryotic genomes reveals clear species boundaries, *Nat. Commun.* 9 (1) (2018) 1–8.
- [11] S. T. Snippy: Fast Bacterial Variant Calling from NGS Reads, 2015. <https://>

- github.com/tseemann/snippy (Accessed J.
- [12] B.P. Alcock, et al., Card 2020: antibiotic resistome surveillance with the comprehensive antibiotic resistance database, *Nucleic Acids Res.* 48 (D1) (2020) D517–D525.
- [13] N. Wang, et al., Analysis of newly detected tetracycline resistance genes and their flanking sequences in human intestinal bifidobacteria, *Sci. Rep.* 7 (1) (2017) 1–10.
- [14] D. Lokesh, R. Parkesh, R. kammara, *Bifidobacterium adolescentis* is intrinsically resistant to antitubercular drugs, *Sci. Rep.* 8 (1) (2018) 1–15.
- [15] L. Masco, et al., Antimicrobial susceptibility of *Bifidobacterium* strains from humans, animals and probiotic products, *J. Antimicrob. Chemother.* 58 (1) (2006) 85–94.
- [16] V. Rozman, et al., Characterization of antimicrobial resistance in lactobacilli and bifidobacteria used as probiotics or starter cultures based on integration of phenotypic and in silico data, *Int. J. Food Microbiol.* 314 (2020), 108388.
- [17] E. Esaiassen, et al., *Bifidobacterium* bacteremia: clinical characteristics and a genomic approach to assess pathogenicity, *J. Clin. Microbiol.* 55 (7) (2017) 2234–2248.
- [18] A. Ohishi, et al., *Bifidobacterium* septicemia associated with postoperative probiotic therapy in a neonate with omphalocele, *J. Pediatr.* 156 (4) (2010) 679–681.
- [19] J. Berrington, N.D. Embleton, Discriminating necrotizing enterocolitis and focal intestinal perforation, *Arch. Dis. Child. Fetal Neonatal Ed.* 107 (2022) F336–F339.
- [20] J.E. Berrington, N.D. Embleton, Time of onset of necrotizing enterocolitis and focal perforation in preterm infants: impact on clinical, surgical, and histological features, *Front. Pediatr.* 9 (2021), 724280.
- [21] E. Esaiassen, et al., *Bifidobacterium longum* subspecies *infantis* bacteremia in 3 extremely preterm infants receiving probiotics, *Emerg. Infect. Dis.* 22 (9) (2016) 1664–1666.
- [22] C. Bertelli, et al., *Bifidobacterium longum* bacteremia in preterm infants receiving probiotics, *Clin. Infect. Dis.* 60 (6) (2015) 924–927.
- [23] A. Zbinden, et al., Case series of *Bifidobacterium longum* bacteremia in three preterm infants on probiotic therapy, *Neonatology* 107 (1) (2015) 56–59.
- [24] C. Alcon-Giner, et al., Microbiota supplementation with *Bifidobacterium* and *Lactobacillus* modifies the preterm infant gut microbiota and metabolome: an observational study, *Cell Rep. Med.* 1 (5) (2020) 100077, 100077.
- [25] M.A. Underwood, E. Umberger, R.M. Patel, Safety and efficacy of probiotic administration to preterm infants: ten common questions, *Pediatr. Res.* 88 (Suppl 1) (2020) 48–55.
- [26] M. Ferrari, et al., Efficient isolation of membrane-associated exopolysaccharides of four commercial bifidobacterial strains, *Carbohydr. Polym.* 278 (2022) 118913, 118913.
- [27] A.M. Ehrlich, et al., Indole-3-lactic acid associated with *Bifidobacterium*-dominated microbiota significantly decreases inflammation in intestinal epithelial cells, *BMC Microbiol.* 20 (1) (2020) 357, 357.